

EDUCATIONAL TRACK FOR RESIDENTS—REVIEW ARTICLE

Basics of Reading Myocardial Perfusion SPECT to Identify Coronary Artery Lesions

Nobutaka Nagano, MD, Akiyoshi Hashimoto, MD, PhD and Tetsuji Miura, MD, PhD, FACC

Received: June 17, 2016/Accepted: July 4, 2016

© The Japanese Society of Nuclear Cardiology 2016

Abstract

In a polar map display, the LAD originates from an area corresponding to 11 o'clock, and the relationship between localization of the culprit lesion and diagonal arteries can be inferred by the extent of decreased perfusion extending from 12 o'clock towards 1 o'clock. The location of a lesion in the LCX main trunk can be inferred by whether decreased perfusion is observed at any level within 2~5 o'clock. Infarction volume depends on the anatomical size of the territories of the PD and AV but not on the location of a culprit lesion in the RCA trunk.

Keywords: Left anterior descending artery, Left circumflex artery, Myocardial perfusion SPECT imaging, Right coronary artery

Ann Nucl Cardiol 2016 ; 2 (1) : 158-161

Detection of myocardial ischemia and differentiation of viable myocardium and non-viable myocardium are crucial for appropriate management of patients with coronary artery disease. In myocardial perfusion SPECT imaging, a complete perfusion defect indicates transmural infarction, and an attenuated perfusion image in the area at risk may indicate non-transmural infarction. By evaluating the extent of residual perfusion within the infarct zone, the amount of viable myocardium can be quantified (1). For accurate assessment of myocardial viability by myocardial perfusion SPECT imaging, it is important to properly match the anatomy of the coronary artery with the location of the abnormality in SPECT images. In this article, we briefly discuss basic methods for identifying an infarct-related artery by use of myocardial perfusion SPECT imaging.

Left anterior descending artery (LAD) disease

In a polar map display of perfusion SPECT imaging (Fig. 1), the LAD originates from an area corresponding to 11 o'clock and sends out the septal branch (Sep) in the 10 o'clock direction and the first and second diagonal arteries (D1 and D2, respectively) in the 12 o'clock direction (2). A decreased

perfusion image in a region between 12 o'clock and 1 o'clock suggests infarcts in the diagonal artery region, and the relationship between localization of the culprit lesion and diagonal arteries can be inferred by the presence or absence of an area of decreased perfusion extending from 12 o'clock towards 1 o'clock. Extension of decreased perfusion from 11 o'clock to an area beyond 12 o'clock (black arrow and dark gray) at any level from the cardiac base to apex (Fig. 1a, b) suggests that the diagonal artery is included in the occluded coronary tree (3). Lack of such an extension of the low perfusion area (white arrow) (Fig. 1c) indicates that the diagonal arteries are not included in the territory of the occluded artery. In cases of infarction due to an LAD occlusion, decreased perfusion most likely appears in peripheral regions of the LAD territory. Thus, confirmation of decreased perfusion in a region between 10 o'clock and 12 o'clock at the apex level makes it possible to differentiate ischemia by an LAD lesion from perfusion attenuation artifacts by the breast (Fig. 2).

Left circumflex artery (LCX)

The LCX runs orthogonal to the LAD from 11 o'clock in

doi : 10.17996/ANC.02.01.158

Nobutaka Nagano, Akiyoshi Hashimoto, Tetsuji Miura
Department of Cardiovascular, Renal and Metabolic Medicine,
Sapporo Medical University School of Medicine, South-1, West-16,
Chuo-ku, Sapporo, Hokkaido, Japan 060-8543
E-mail: ahashimo@sapmed.ac.jp

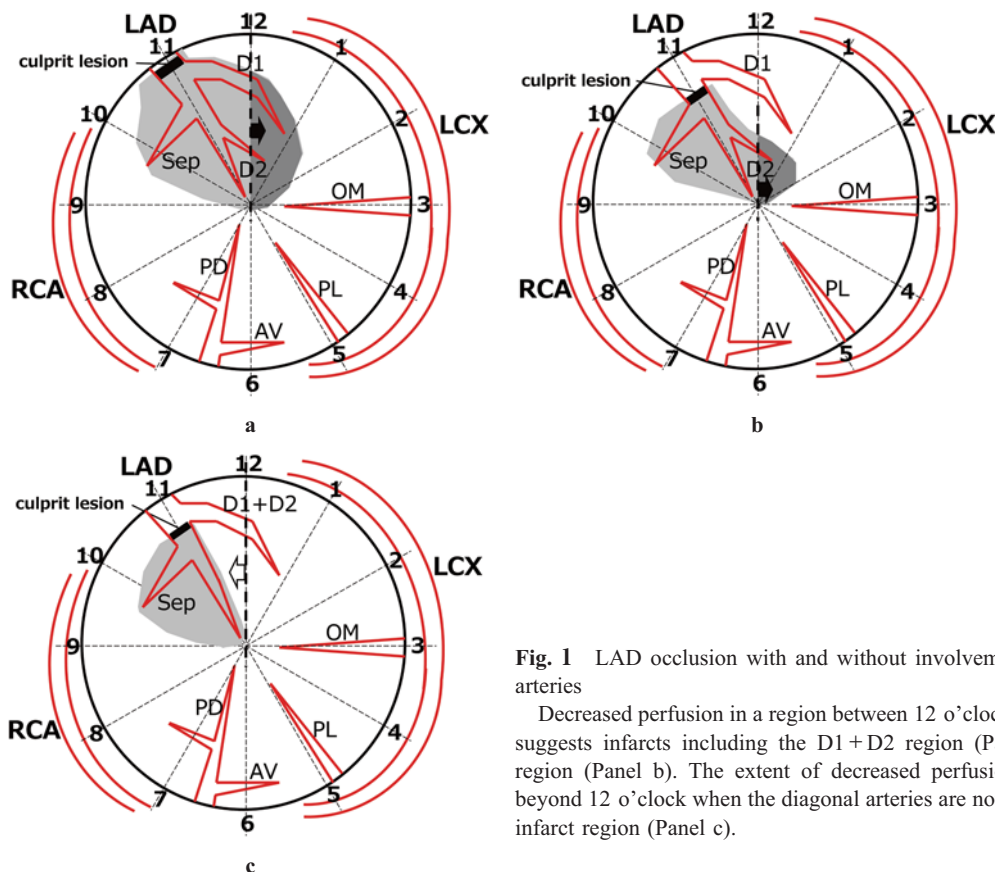
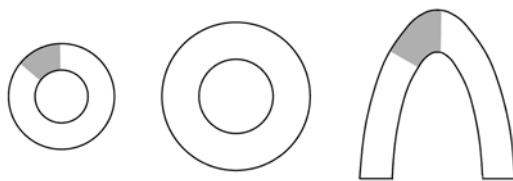


Fig. 1 LAD occlusion with and without involvement of diagonal arteries

Decreased perfusion in a region between 12 o'clock and 1 o'clock suggests infarcts including the D1+D2 region (Panel a) and D2 region (Panel b). The extent of decreased perfusion does not go beyond 12 o'clock when the diagonal arteries are not included in the infarct region (Panel c).

a. LAD lesion



b. breast attenuation

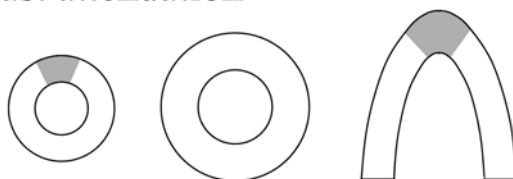


Fig. 2 LAD ischemia vs. breast attenuation

Difference in the location of decreased perfusion at the apex level between infarction due to an LAD lesion and breast attenuation.

the polar map, and the obtuse marginal branch (OM) at 2~3 o'clock and the posterolateral branch (PL) at 4~5 o'clock are sent out from the LCX running in the left atrioventricular groove (left margin of the polar map) (Fig. 3). The location of the lesion (stenosis or occlusion) in the LCX main trunk can be inferred by whether decreased perfusion is observed at any level within 2~5 o'clock (Fig. 3a, b) (4). Infarction by an OM lesion is shown by decreased perfusion localized at 3 o'clock (Fig. 3c).

Right coronary artery (RCA)

The RCA runs in the right atrioventricular groove (right margin of the polar map) and sends out the posterior descending artery (PD) at around 7 o'clock, and then the atrioventricular node artery (AV) is branched from the PD toward the 6~5 o'clock region (Fig. 4). Infarction in the PD region is shown as decreased perfusion spreading in a radial direction (Fig. 4a). In contrast, infarction due to an occluded AV artery is shown as decreased perfusion spreading in the circumferential direction (Fig. 4b). It is not possible to differentiate cases with a culprit lesion being in a proximal segment of the RCA (Fig. 5a) from cases with a lesion in a distal segment of the RCA (Fig. 5b) because infarct volume depends only on the size of myocardial mass perfused by the PD and AV.

The myocardial area at risk after infarction contains a mixture of viable and necrotic myocardium, and that heterogeneity in the SPECT image depends not only on the severity of stenosis by the culprit lesion but also on the anatomical course of the artery with a culprit lesion in the ventricle and level of collateral flow (5). Detection of myocardial viability in a SPECT image that is appropriately matched with the course of the coronary artery has been shown to be useful for selecting revascularization strategies (6). In the present article, we described basics of reading a myocardial perfusion SPECT image for diagnosis of the coronary artery disease. More detailed information regarding the use of

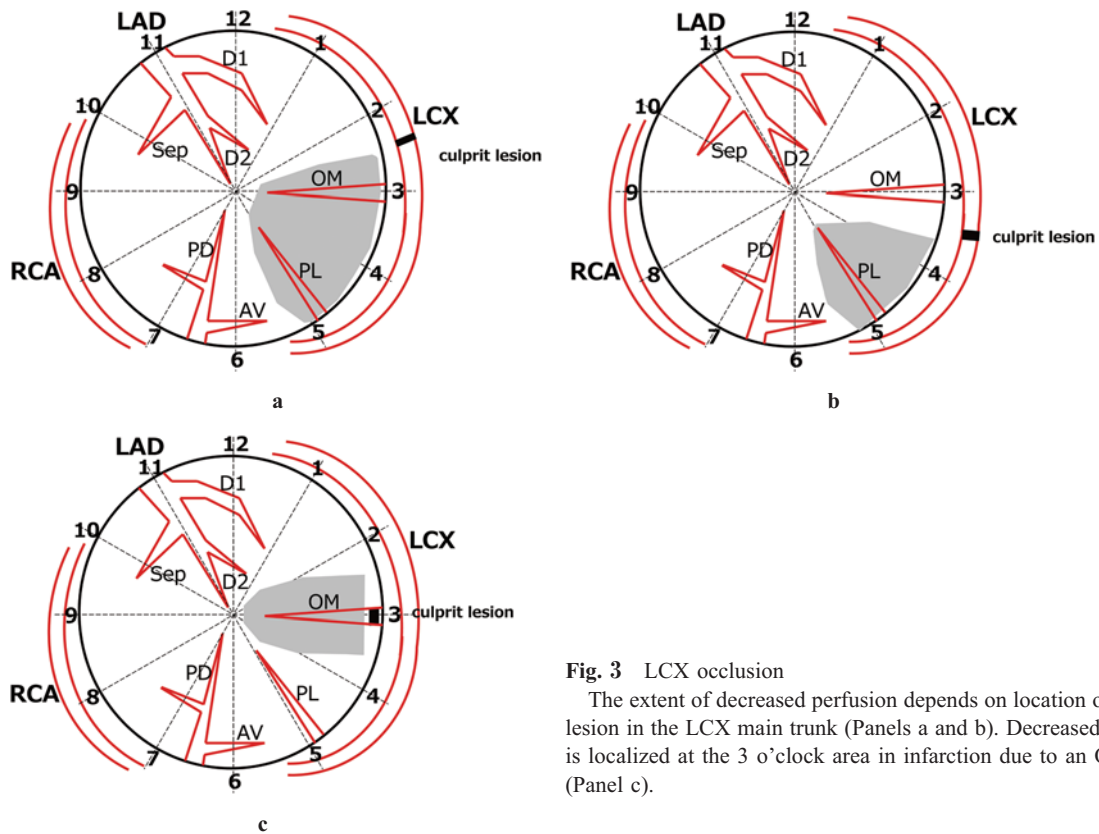


Fig. 3 LCX occlusion

The extent of decreased perfusion depends on location of a culprit lesion in the LCX main trunk (Panels a and b). Decreased perfusion is localized at the 3 o'clock area in infarction due to an OM lesion (Panel c).

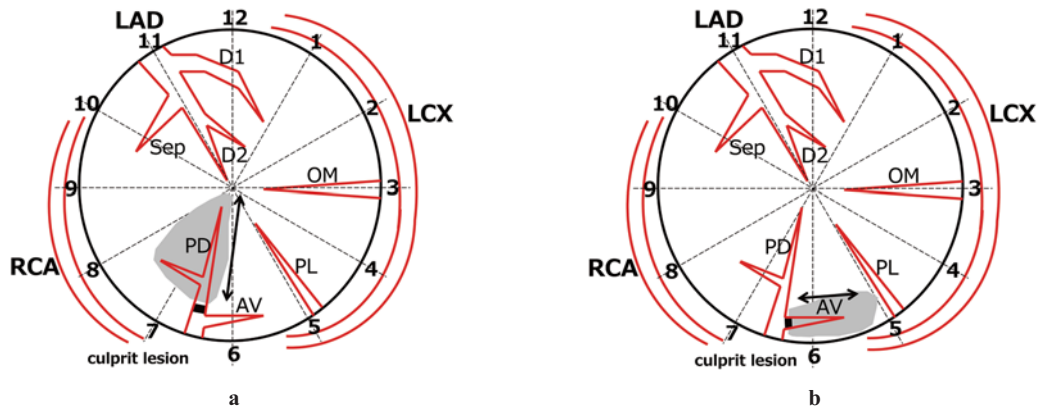


Fig. 4 PD occlusion vs. AV occlusion

Decreased perfusions spreading in the radial direction and the circumferential direction suggest occlusion in the PD (Panel a) and that in the AV (Panel b), respectively.

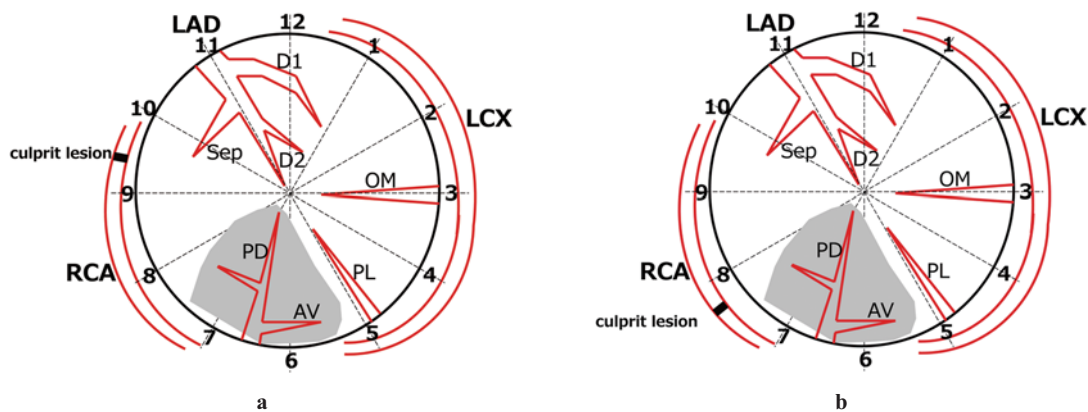


Fig. 5 RCA occlusion

Infarction volume depends on the anatomical size of the territories of the PD and AV but not on the location of a culprit lesion in the RCA trunk. Panel a, occlusion in a proximal segment of the RCA; Panel b, occlusion in a distal segment of the RCA.

perfusion SPECT imaging for diagnosis and management of coronary artery disease has been published elsewhere (7,8).

Contributorship

Dr Nagano and Dr Hashimoto planned this review article for interpreting myocardial perfusion SPECT to identify coronary artery lesions. Professor Miura comprehensively conducted our work and will accept responsibility for the integrity of the work as a whole.

Acknowledgments

The authors thank Yoko Tamura for assistance in preparing the manuscript.

Sources of funding

None

Conflicts of interest

None

Abbreviation and Acronyms

AV: atrioventricular node artery

D1: first diagonal artery

D2: second diagonal artery

LAD: left anterior descending artery

LCX: left circumflex artery

OM: obtuse marginal branch

PD: posterior descending artery

PL: posterolateral branch

RCA: right coronary artery

Sep: septal branch

SPECT: single photon emission computed tomography

Reprint requests and correspondence:

Akiyoshi Hashimoto, MD, PhD

Sapporo Medical University School of Medicine, Department of Cardiovascular, Renal and Metabolic Medicine, South-1, West-16, Chuo-ku, Sapporo, Hokkaido Japan 060-8543

E-mail: ahashimo@sapmed.ac.jp

References

1. Tsukamoto T, Gotoh K, Yagi Y, et al. Usefulness of resting thallium-201 delayed imaging for detecting myocardial viability in patients with previous myocardial infarction. *Ann Nucl Med* 1993; 7: 79-86.
2. Tanaka T, Aizawa T. Diagnosis of left anterior descending artery lesion. *Cardioangiology* 1993; 34: 288-92.
3. Tanaka T, Aizawa T. Characteristics of diagonal branch lesion. *Cardioangiology* 1993; 34: 420-5.
4. Tanaka T, Aizawa T. Ischemic region of postero-descending artery and posterolateral artery. Anatomical superiority and functional superiority. *Cardioangiology* 1995; 38: 381-90.
5. Rigo P, Becker LC, Griffith LSC, et al. Influence of coronary collateral vessels on the results of thallium-201 myocardial stress imaging. *Am J Cardiol* 1979; 44: 452-8.
6. Shaw LJ, Berman DS, Maron DJ, et al. Optimal medical therapy with or without percutaneous coronary intervention to reduce ischemic burden results from the clinical outcomes utilizing revascularization and aggressive drug evaluation (COURAGE) trial nuclear substudy. *Circulation* 2008; 117: 1283-91.
7. Heller G, Hendel R. *Nuclear cardiology: practical applications*, second edition. McGraw-Hill Prof Med/Tech, USA, 2010.
8. Cerqueira MD, Adelmann G. *Cardiac Imaging Secrets, Radionuclide Tracers, Methods: Planar and Positron Emission Tomography, Protocols, and Assessment of Left Ventricular Function*. p 139-63, Hanley & Belfus, USA, 2004.